



Remote screening of retinal and optic disc diseases using handheld nonmydriatic cameras in programmed routine occupational health checkups onsite at work centers

Miguel A. Zapata^{1,2} · Ruth Martín³ · Claudia Garcia-Arumí⁴ · Alex Fonollosa² · Ignacio Flores-Moreno² · Roberto Gallego-Pinazo² · Estanislao Gutiérrez² · Maximino Abalades² · Javier Zarranz-Ventura^{4,5} · On behalf Optretina Reading Group

Received: 22 April 2020 / Revised: 20 July 2020 / Accepted: 23 July 2020
© Springer-Verlag GmbH Germany, part of Springer Nature 2020

Abstract

Purpose To evaluate the first year outcomes of a remote screening program for detection of retinal diseases using handheld nonmydriatic cameras in occupational routine checkups performed onsite at work centers.

Methods Cross-sectional, first year screening program outcomes audit. Participants were volunteers recruited from staff within work centers. Retinal fundus images were captured by technicians, and images and data were anonymized and sent securely to a remote server. A team of ophthalmologists, all retinal specialists, remotely read the images using a custom-made software and sent telematic reports of findings within 24–48 h. The main items evaluated were the detection of retinal abnormalities and the relationship between retinal findings and demographic data such as age and sex.

Results A total of 19,881 workers were evaluated in 52 centers. Mean age was 41.1 years old, 43.9% men and 56.1% women. Mean duration of the test was around 2 min. Of the workers, 7.8% presented abnormalities in retinal fundus images, being the main findings choroidal nevus (2.4%), macular pigment abnormalities (1.5%), glaucomatous optic disc (1.2%), and macular signs of high myopia (1.1%). The presence of abnormalities was associated with greater age, being 5%, 7.9%, 12.6%, and 19.7% in workers less than 40 years, from 40 to 49, 50–59, and ≥ 60 years ($p < 0.05$), respectively. Men had more abnormalities in retinal fundus images than women (8.6 vs. 7.2; $p < 0.05$ RR: 1.2; CI 1092–1322).

Conclusions Mass screening of retinal and optic disc abnormalities during occupational health routine checkups is a feasible, quick, and efficient tool for early detection of potential vision-threatening disease markers.

Keywords Screening · Telemedicine · Retinal diseases · Optic nerve diseases · Occupational health

Introduction

Routine occupational health checkups for employees are commonly organized in a periodical basis by employers and companies in many countries. Regulations differ between countries, being mandatory or voluntary depending on the framework, except in certain sectors such as the chemical industry or other industries where the job itself implies a specific risk for the workers. In Spain, the regulation of Occupational Risk Prevention Services arranges medical checkups before starting work (for the first time or after a long time off) and periodically, normally once a year. Medical revisions should be carried out by qualified personnel and should always be supervised by a medical specialist in occupational health. A routine occupational health examination usually consists of a general past medical history of the worker's health status and a

✉ Miguel A. Zapata
mazapata@optretina.com

¹ Optretina, C/ Las Palmas 11, 08195 Sant Cugat del Vallès, Barcelona, Spain

² Optretina Image Reading Team, Barcelona, Spain

³ Hospital Vall Hebron, Barcelona, Spain

⁴ Hospital Clínic of Barcelona, Barcelona, Spain

⁵ Institut de Investigacions Biomediques August Pi Sunyer (IDIBAPS), Barcelona, Spain

Key messages

- The diseases of the central retina and glaucoma are the first cause of visual loss in industrialized countries. They are asymptomatic diseases. Its early diagnosis has proven useful in avoiding visual loss. So far, no screening of these diseases is carried out in the occupational environment.
- Screening of diseases of the central retina through non-mydratic cameras is an effective and efficient system.
- Between 7 and 8% of the active population has alterations in the retina that must be controlled, this percentage increases exponentially with age
- Screening of retinal abnormalities during occupational routine checkups seems to be a good tool for early detection of vision-threatening disease. It should be incorporated into the usual occupational reviews as it would efficiently ensure the employees' visual health

structured general physical examination. Routinely, other complementary tests are often included in the reviews such as a control of the best corrected visual acuity, an audiometry, a spirometry, an electrocardiogram, and blood and urine analysis with standard profiles (i.e., full blood count, glucose, U&E, etc.). In some cases, other tests such as radiology studies may be included. Similar checkups are carried out in other countries of the European Union and North America as a previous assessment to start a job [1, 2]. Although no data or extensive studies on the general prevalence of injuries are available, previous studies have reported a positive impact of these reviews on certain aspects, such as enhancing respiration [3], improving diet [4], assessing low back pain [5], or providing economic data that demonstrate absenteeism reduction in companies with these types of examinations [6].

There is a literature lack about the role of ophthalmology in these routine occupational health checkups, and only few studies have been reported. These scarce publications support the need for periodic ocular reviews and highlight the value of vision and the importance of visual health prevention, especially in elderly patients [7, 8]. In modern societies, in the developed world, the diseases of the central retina and glaucoma are the most frequent cause of severe visual loss [9]. These diseases are completely asymptomatic in early stages and slowly progress to greater stages when symptoms developed and diagnosis is made. Unfortunately, at this late stage, often lesions are permanent and the possibility of visual recovery is marginal. Therefore, early diagnosis of these diseases of the central retina and optic nerve appears essential,

and previous reports have demonstrated its benefits in preserving patient's vision [10, 11].

This work aims to evaluate the first year outcomes of a remote screening program for detection of retinal diseases using handheld nonmydratic cameras, in occupational routine checkups performed onsite at work centers. This pilot study is directed to assess the feasibility of this innovative approach, in order to establish its validity and potential benefits prior to be incorporated in routine occupational health checkups protocols.

Methods

A retrospective study was carried out, based on the first year of retinal screening during routine labor reviews.

Registration

Employee participation was voluntary; they were given all the information about the test performed, its benefits, and limitations. All patients signed the consent form to perform the test and the data protection law. After that, all participants completed an online form with their age and their medical background. Once the form was filled, the participants received an appointment for the retinal fundus image, indicating the date and the room where the test would take place and the exact time of the test.

Imaging protocol

The images were taken at the same offices, inside rooms with poor lighting prepared for retinal fundus image with nonmydriatic cameras. The images were captured by technicians specially trained for it. The cameras used were handheld nonmydriatic cameras, Optomed Smartscope PRO model, Zeiss visuscout 100 and Optomed Aurora, and examples of different images and camera characteristics are shown in Fig. 1. At the time of the appointment, the patients identified themselves, and the technicians used their tablets to get their data and the QR code assigned to each patient. The technicians performed the retinal fundus images of each patient next to the photography of the QR codes using Optretina's own software (Fig. 2). Then when the cameras were connected to the network, the images were directly assigned to the patient's data and were automatically processed, anonymized, and loaded into Optretina's telemedicine platform to be evaluated by ophthalmologists.

Retinal fundus image evaluation

The software and the evaluation of the cases by Optretina were previously described for screening in optical centers [12]. The software accomplishes the requirements of anonymization, data protection, and security demanded (CE marking, HL7). The evaluation was performed by twelve retina ophthalmologists experienced in image evaluation.

Case distribution among experts was randomized. The reports described the findings in the retinal fundus images, and a visit to the ophthalmologist was recommended to all those patients who presented abnormalities in the retinal fundus image, including those ones with characteristics that may not be pathological in some cases, such as small nevus, drusen, or pigment. International pathology criteria were used for the evaluation (diabetic retinopathy, age-related macular degeneration (AMD), and suspected glaucomatous optic neuropathy) [12]. Cases with blurred images not good enough for evaluation were also referred to the ophthalmologist in order to study possible causes as cataract, corneal opacities, and other.

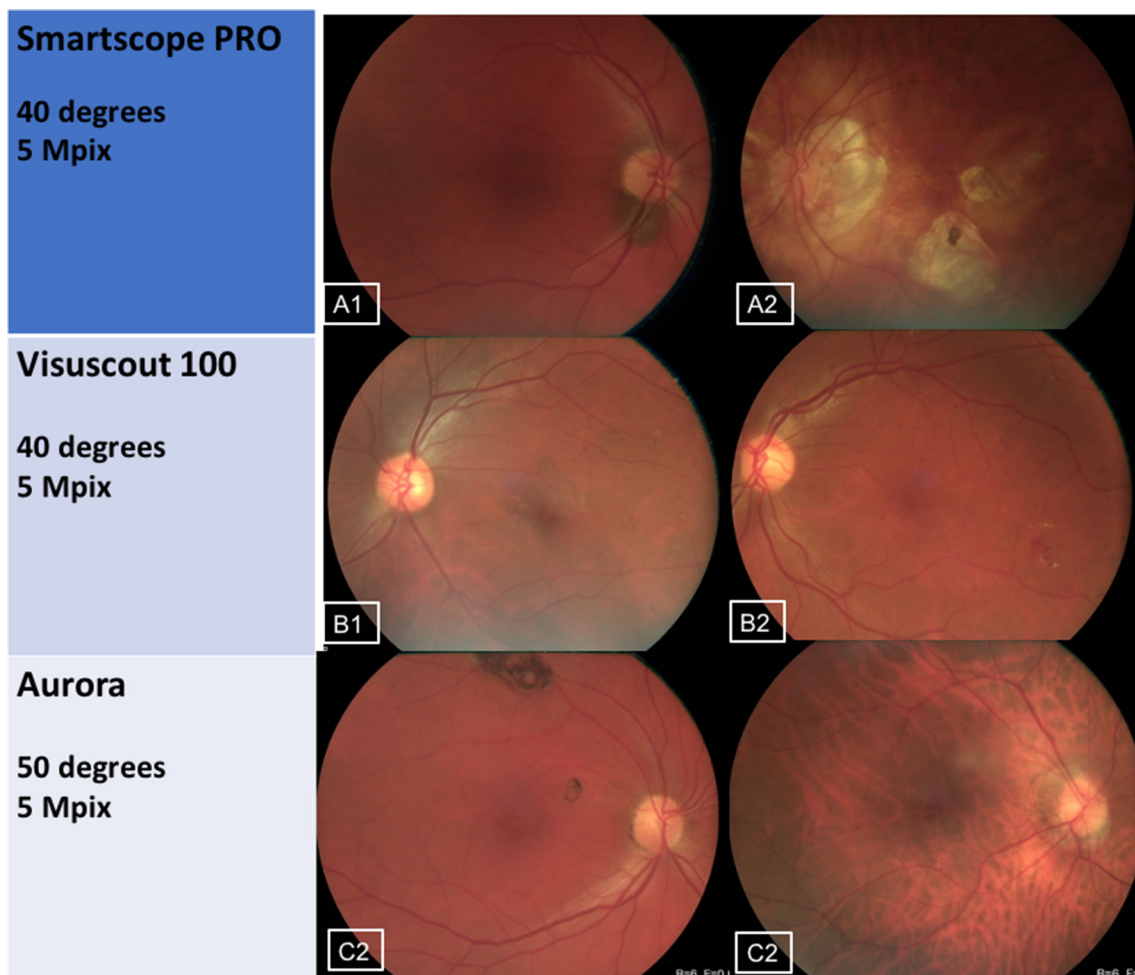


Fig. 1 Example of fundus photographs with different models of handheld cameras. Images performed with Smartscope PRO: (A1) peripapillary choroidal nevus and (A2) myopic fundus with atrophy and Fuchs' spot.

Images captured with Visuscout 100: (B1) macular pigmented abnormalities and (B2) diabetic retinopathy. Images from Aurora: (C1) Retinal scars and (C2) tessellated fundus

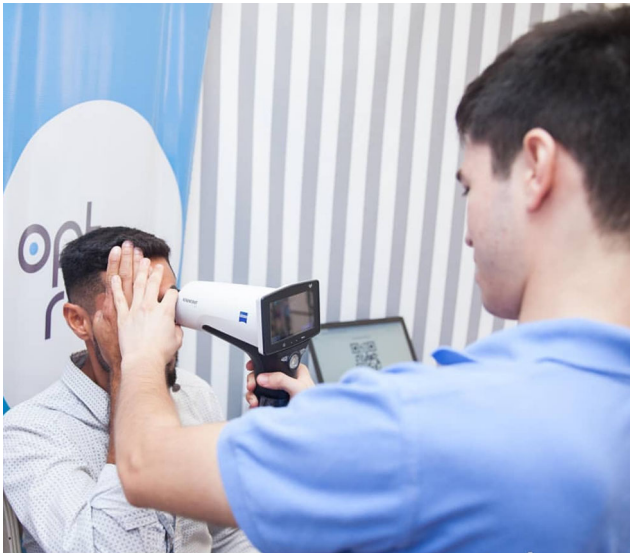

Fig. 2 Demonstration of retinal fundus imaging, using handheld camera, and preregistration with QR codes

Once the cases were reviewed, a report was sent to each patient (in some cases through the company medical staff) with test's results and recommendations. The test was funded by the insurance company or by the company itself.

Awareness

During the test, we took the opportunity to raise awareness among workers about the importance of visual health. It was orally performed by the technicians who took the images, and the results reports were given in a written way. General advice on avoiding toxics, the importance of a good nutrition, and periodic ophthalmological checkups was added.

Level of satisfaction

The insurance company Sanitas (member of BUPA) conducted a satisfaction survey in several of the offices where the screening was carried out, asking employees: global satisfaction, professionalism of technicians/doctors and level of recommendation.

Patient and public involvement

Patients and the public were not involved in the design or conduct or reporting or dissemination plans of the research.

Ethical considerations

Optretina is a company supervised by the ethical committee of the Vall d'Hebron Hospital in Barcelona, who approved the review and publication of these data, number PR(OPT)370/

2019. Informed consent was obtained from all individual participants included in the study.

Statistical study

For the statistical study, the IBM SPSS Statistics version 23 was used. For the comparison of age average between groups, the Student's *t* test was used for independent data. We use the chi-square test to evaluate qualitative variables with 2×2 tables.

Results

A total of 19,881 patients were evaluated, distributed in 52 work centers. The average of employees evaluated per center was 382. The maximum number of workers evaluated in 1 day was 1340, using a team of three camera operators. The average time to perform the test was around 2 min for each patient.

The age average was 41.1 years, with a range between 18 and 70 years, standard deviation 9.71. There were 43.9% of men and 56.1% of women. Only 1.4% of patients were recognized as diabetics. Table 1 summarizes findings depending on age group.

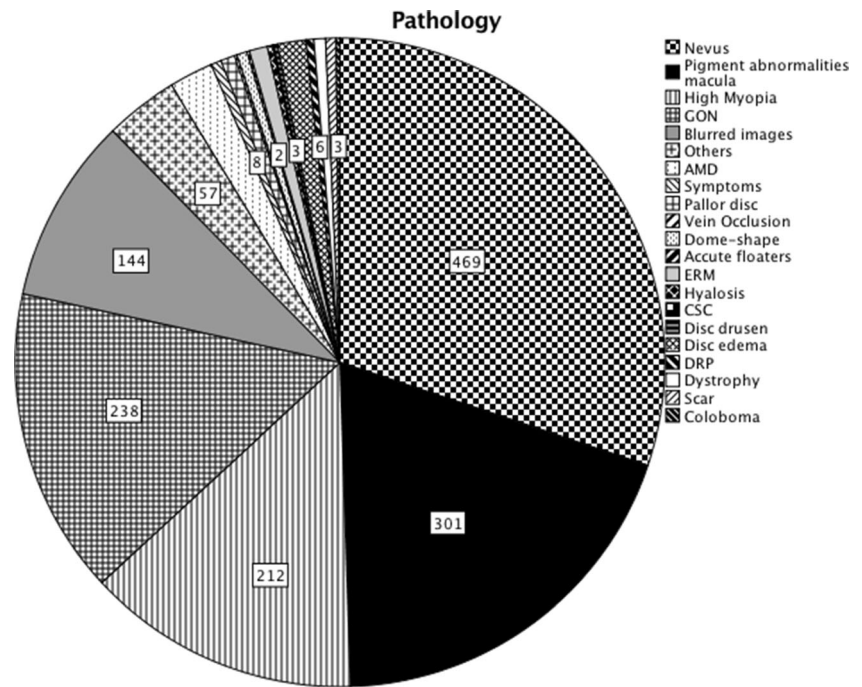
Of the total number of cases evaluated, 7.8% presented retinal fundus image abnormalities and were referred for an ophthalmological review. The main abnormalities found after fundus images evaluation were as follows: choroidal nevus 469 patients (2.4% total), pigmentary abnormalities in macular area 301 patients (1.5%), suspected glaucomatous optic neuropathy 238 patients (1.2%), and signs of high myopia 212 patients (1.1%). Only 0.7% of all patients in 144 cases presented blurred images with an insufficient quality for evaluation, either due to lack of media transparency or due to the presence of small pupils. Figure 3 defines the totality of abnormalities found.

The average age of patients with fundus abnormalities was higher than normal patients (45.19 vs. 40.83 $p < 0.05$). In patients with less than 40 years, the prevalence of abnormalities was 5%, in the group from 40 to 49 years was 7.9%, and in the group from 50 to 59 years was 12.6%, and retinal abnormalities were present in the 19.7% of patients over 60 years ($p < 0.05$) (Fig. 4). Males presented more alterations in retinal fundus images than females (8.6 vs. 7.2; $p < 0.05$ RR: 1.2; CI 1092–1322). Such differences increased with age; in over 50 years, the prevalence of abnormalities is 15.22 in men and 11.72 in women ($P = 0.001$; RR1.3; CI 1114–1517). There were no significant differences between men and women in the prevalence of nevus, high myopia, or macular pigmentary abnormalities. Men presented more frequently a suspected glaucomatous optic neuropathy (1.4% vs. 1.03%; $p = 0.018$; RR: 1.36; CI 1.62–1.76). Of the total cases in which a medical review was recommended, 97.4% were routinely referred, 2.2% were referred as a priority, and 0.4% of patients were referred urgently to the ophthalmologist.

Table 1 Patients distribution and fundus image finding depending on age group

Age group	<40 years		40–49 years		50–59 years		≥60 years		Total	
	Patients	Percentage	Patients	Percentage	Patients	Percentage	Patients	Percentage	Patients	Percentage
Number of patients	8405	100.0	7269	100.0	3751	100.0	456	100.0	19,881	
Gender										
Female	4657	55.4	4260	58.6	2043	54.5	194	42.5	8727	43.9
Male	3748	44.6	3009	41.4	1708	45.5	262	57.5	11,154	56.1
Diabetic patients	69	0.8	77	1.1	116	3.1	25	5.5	287	1.4
Retinal fundus abnormalities	421	5.0	573	7.9	472	12.6	90	19.7	1556	7.8
Choroidal Nevus	142	1.7	201	2.8	114	3.0	12	2.6	469	2.4
Macular pigment abnormalities	72	0.9	123	1.7	93	2.5	13	2.9	301	1.5
GON	69	0.8	81	1.1	80	2.1	8	1.8	238	1.2
High myopia	67	0.8	81	1.1	58	1.5	6	1.3	212	1.1
Blurred images	23	0.3	37	0.5	54	1.4	30	6.6	144	0.7
AMD	0	0.0	0	0.0	16	0.4	14	3.1	30	0.2
Others	48	0.5	50	0.7	57	1.7	7	1.4	162	1.6
Routine	410	95.0	560	7.7	456	12.2	90	19.7	1516	7.6
Preferential	10	4.9	12	0.2	12	0.3	0	0.0	34	0.2
Urgently	1	0.1	1	0.0	4	0.1	0	0.0	6	0.0

Fig. 3 Representation of the main abnormalities found in the retinographies and their absolute numbers of the total series. GON, glaucomatous optic neuropathy; AMD, age-related macular degeneration; ERM, epiretinal membrane; CSC, central serous chorioretinopathy; DRP, diabetic retinopathy



The cost of the test per patient was less than 10 euros, depending on the volume of employees assessed by each center.

The percentage of workers who underwent the fundus image examinations of the total workforce varied between centers and oscillates between 60 and 92% of the employees. A satisfaction survey was requested to 930 employees. The average satisfaction score was 9.1 out of 10. Professionals received 9.35 out of 10. Ninety-five percent of the employees would recommend it to a friend, and 95% would repeat the exam in the future.

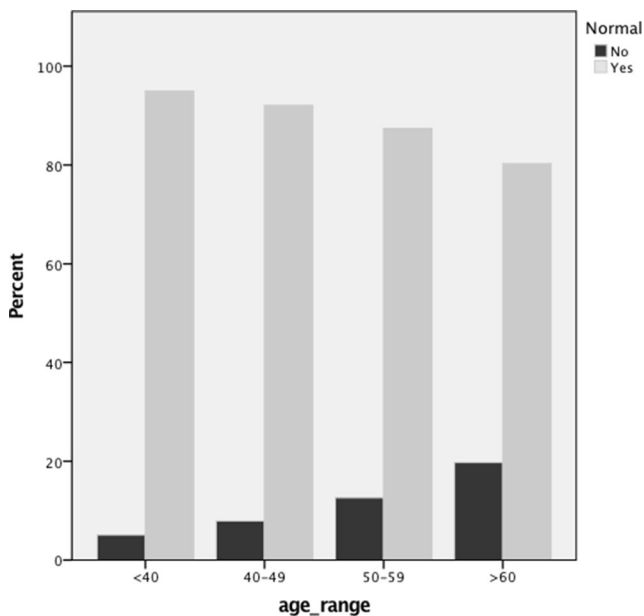


Fig. 4 Distribution of retinal fundus abnormalities depending on age groups

Discussion

The convenience of performing routine medical exams in the workplace remains controversial. Meanwhile, it is accepted that such examinations may help to promote workers health and may contribute to prevent illnesses and sometimes can be a barrier especially when these examinations are done prior to getting the job. From the deontological perspective, there is a potential risk that these studies may prevent equal labor access for certain individuals [13, 14]. Leaving aside this previous examination, the promotion of health and periodic reviews at workplaces have been proven effective and efficient in improving the health of employees [3, 6], especially in some types of jobs and specific groups.

For years, a visual acuity assessment is carried out during routine pre-employment medical exams in most European countries. Vision is critical for many of the existing jobs, since the vision is our main communication system with the environment that surrounds us. A simple visual acuity check may be important, for example, in the early diagnosis of cataracts, but it can be ineffective to prevent the main diseases that cause blindness or decrease of vision in our environment. Diabetic retinopathy, glaucoma, and AMD are completely asymptomatic until advanced stages of the disease, and early interventions are required to prevent or detect these diseases before permanent damage is established. In this aspect, retinal fundus images with nonmydriatic cameras have widely demonstrated their value. Its efficacy and efficiency for early detection of diabetic retinopathy [15] and AMD [16] are widely demonstrated, and recent reports suggest positive screening outcomes also in glaucoma and neurological diseases [17, 18].

In our series, abnormalities have been found in 7.8% of the patients, significantly lower than the 21% found by our same group in patients who were assessed in optical centers [12]. We think that this difference may be explained by a number of reasons, such as age, which is allegedly much lower in occupational health checkups than in the general public (41.1 years vs. 52.3 years). In addition, patients who come to the optician may present some selection bias, as they may have a reason to seek for ophthalmic care. We do believe that our current series may be closer to the general population of working age. As expected, in our series, the prevalence of retinal abnormalities increases with age. Although it is a very inexpensive screening method that could be successful for the entire population, it could make sense establish priority, for reasons of cost-effectiveness, for patients over 50 years of age or with risk factors.

The main finding has been the choroidal nevus. The prevalence of nevus in the population ranges between 0.5 and 7% depending on the series, age, and race [19]. In our series, we had a prevalence of nevus of 2.4% of the total fundus pictures examined, consistent with the average age of our cohort. No prevalence studies in Spanish or European population have been reported, although it seems to be higher in white Caucasian race and decreases in more pigmented races such as black or Hispanic race [20]. The importance of the detection and control of nevus consists in its possible malignancy to choroidal melanomas. It has been classically estimated that approximately one in 8000 nevus become malignant melanomas [21], although this figure has been questioned by other authors, who suggest that the probability for a nevus to become malignant in a lifespan can be up to 1% [22]. The diagnosis and ophthalmological control of the nevus, especially those that show risk factors, is key for early detection and prompt treatment in case of malignant transformation [20]. Pigmentary alterations are the second cause of referral to the ophthalmologist in our series. Whereas such lesions are not a disease themselves, they are a common feature that represents a miscellaneous group of diseases from multiple etiologies. In our previously published optical center screening series, they represented 7% of all reported lesions [12]. Possible etiologies for pigmentary alterations include unconventional forms of AMD, sequelae of previous central serous chorioretinopathy, traumatic or phototraumatic lesions, or incomplete forms of macular dystrophies, among other less frequent conditions. In all these situations, a complete ophthalmological assessment and the performance of further ancillary tests, such as optical coherence tomography or autofluorescence, are essential for differential diagnosis and correct management of such cases.

The global prevalence of glaucoma worldwide is 3.5% in the general population between 40 and 80 years [23], being significantly lower in Europe where it has been reported below 3%. In our series, the prevalence of suspected glaucoma defined as possible glaucomatous papilla has been lower, 1.2%. This figure may be explained at least in part for the

younger age of our study cohort. We must remember that the definitive diagnosis of glaucoma is very complex to perform and requires a complete ophthalmological examination and other complementary tests. In previous reports, the presence of glaucomatous papilla in retinal fundus images performed for diabetic retinopathy screening in the UK [24] was 1.87%, slightly higher than our prevalence. Consistent with this data, it is known that diabetics may have a higher prevalence of glaucoma than the general population. Nevertheless, the study of suspicious papilla in retinal fundus images has been proposed as a good method for glaucoma screening [24, 25], although it is performed opportunistically during the screening of other diseases such as diabetic retinopathy or AMD. The greater experience and training of glaucoma specialists in the evaluation of the optic disc could, in theory, make the suspicion of glaucoma more accurate. Other studies have seen good intra- and interobserver agreement among ophthalmologists, optometrists, and even non-medical qualifiers [26–28]. In our case, we have models similar to other detection programs that evaluate the retina and also the optic disc, such as in Hong Kong or the UK, where glaucoma specialists [24, 29] are not used. More research is needed in this area, for example, establishing staggered screening between subspecialties.

Macular disorders associated with high myopia have been the fourth most frequent cause of abnormality. The prevalence of myopic maculopathy in the general population varies depending on race, but as a general rule, it is estimated to be between 1 and 4% [30]. In our series, it has accounted for 1.1%, consistent with this previous report. Myopic maculopathy is one of the most frequent causes of visual loss and blindness in our environment, especially in young people, hence the importance of its ophthalmological detection and control in working age individuals such as those evaluated in the present series. We must emphasize that high myopia is one of the leading causes of severe visual impairment and legal blindness, being in Spain the first cause of affiliation with the national organization of blind people (*Organización Nacional de Ciegos de España, ONCE*) [31].

Handheld cameras have been used previously for retina and optic disc screening [32, 33], and they have been compared, with good results, with stand-alone nonmydriatic cameras [34]. The quality of the images for screening is a key point. In our case, 0.7% of the patients did not have images of sufficient quality. The blurring of retinal fundus images can be due to multiple causes, although with well-trained technicians and in rooms with the right conditions the main causes are usually the presence of media opacity or the presence of very small pupils. Our series presents a much lower percentage of non-evaluable cases compared with other series [35], where they range between 8 and 18%. In our opinion, this better performance may be explained due to the younger average age of evaluated individuals and adequate training in the

image capture process. For the latter, the formula employed in this study, with a specialized team performing the examinations locally at workcenters, appears as an excellent tool to improve the quality of the images for future remote assessment and therefore the reliability of the findings.

Consistently with the average age of the evaluated cohort, the presence of AMD suggestive lesions was low (0.2%), as expected compared with other prevalence studies in older study populations. Nevertheless, even in the subgroup analysis by age group, the prevalence of AMD signs is 0.7% in individuals older than 50 years, lower than the prevalence data published for this age group [36]. Our series mainly include office workers which allegedly present adequate health, but we do not have toxicological (smoker/nonsmoker) or dietary intake data that could help us inform further the reasons for this lower prevalence of AMD. Although the use of remote fundus photography has been used primarily for screening of DR, there is a very low prevalence of diabetes in the study population. Signs of DR were only observed in 6 patients, making it difficult to draw conclusions regarding this disease.

Employee satisfaction with the test was very high, due to the simplicity of the test, its speed, and especially the fact of being carried out in the same workplace. Although this is not a cost-effectiveness study, we can state that the cost per patient was much lower than other retinal screenings, especially performed in diabetic patients. The cost estimates for a single examination with the protocol and setting proposed in this study is 10 euros per patient (maximum), much lower than the usual cost estimated for a conventional DR screening visit, which ranged from 20 to 100 euros, depending on the series [37].

First, the retrospective nature of the data collection. Second, the potential risk of selection bias, as the examinations were carried out in an office environment. Second, there is a potential risk of selection bias, as the study population has been identified and the examinations have been carried out in an office environment. Meanwhile, the latter circumstance limits the generalization of the results to the overall population; it would be interesting to include workers from other sectors, as industrial, primary, or service sectors, to have a general view of the prevalence of retinal and optic nerve pathologies in the overall workforce nationwide.

We believe that new strategies are needed for the early detection of ophthalmic diseases, even more after the COVID-19 pandemic, simple and fast tools that do not require patient mobility or overburden health care services. In this regard, remote fundus photography can help us as part of the strategy.

In summary, meanwhile we do acknowledge that the percentage of pathology found is low as expected in an allegedly healthy study population and the alterations found are significant enough to justify the examination. The search for retinal lesions by retinal fundus images seems to meet the standards that an effective screening system must have: highly prevalent and potentially incapacitating diseases in the general

population, in which prognosis improves significantly with early diagnosis and treatment, detectable with a simple, non-invasive, low-cost examination. We believe that raising awareness of the role of retinal screening campaigns in the workforce population should be emphasized. New prospective studies will be necessary to confirm the positive preliminary results obtained, especially in other productivity sectors and in other countries, to provide further evidence to support the inclusion of retinal fundus image exams in the routine occupational health checks of the workers.

Authors' contributions All authors have contributed to the study according to international consensus on authorship and have seen and approved the final draft here submitted.

Data availability All data and materials are available from Optretina and no material available for general population due to European data protection law.

Compliance with ethical standards

All procedures performed in studies involving human participants were in accordance with the ethical standards of the institutional and/or national research committee and with the 1964 Helsinki declaration and its later amendments or comparable ethical standards. Informed consent was obtained from all individual participants included in the study. Ethical committee of the Vall d'Hebron Hospital in approved this study with reference PR(OPT)370/2019.

Conflicts of interest MZ is a founder and medical director in Optretina. GA, AB, AF, IF, RG, EG, AO, SP, JR, CS, and MA are retinal specialist and retinal image readers in Optretina. JZV is a retinal specialist.

Code availability Not applicable

References

1. Pachman J (2009) Evidence base for pre-employment medical screening. *Bull World Health Organ* 87(7):529–534
2. Schaafsma FG, Mahmud N, Reneman MF, Fassier JB, Jungbauer FH (2016) Pre-employment examinations for preventing injury, disease and sick leave in workers. *Cochrane Database Syst Rev* 12(1):CD008881
3. Wilken D, Baur X, Barbinova L, Preisser A, Meijer E, Rooyackers J, Heederik D (2012) ERS task force on the management of work-related asthma. What are the benefits of medical screening and surveillance? *Eur Respir Rev* 21(124):105–111
4. Ni Mhurchu C, Aston LM, Jebb SA (2010) Effects of worksite health promotion interventions on employee diets: a systematic review. *BMC Public Health* 10:62
5. Petit A, Rousseau S, Huez JF, Mairiaux P, Roquelaure Y (2016) Pre-employment examination for low back risk in workers exposed to manual handling of loads: French guidelines. *Int Arch Occup Environ Health* 89(1):1–6
6. Burton WN, Chen CY, Conti DJ, Schultz AB, Edington DW (2002) The value of the periodic executive health examination: experience at Bank One and summary of the literature. *J Occup Environ Med* 44(8):737–744 Review

7. Hammond S, Bowen PG, Hallman MG, Heaton K (2019) Visual performance and occupational safety among aging workers. *Workplace Health Saf* 10:2165079919848444
8. Nylén P, Favero F, Glimme S, Teär Fahnehjelm K, Eklund J (2014) Vision, light and aging: a literature overview on older-age workers. *Work* 47(3):399–412
9. Bourne RR, Stevens GA, White RA, Smith JL, Flaxman SR, Price H, Jonas JB, Keeffe J, Leasher J, Naidoo K, Pesudovs K, Resnikoff S, Taylor HR (2013) Vision Loss Expert Group. Causes of vision loss worldwide, 1990–2010: a systematic analysis. *Lancet Glob Health* 1(6):e339–e349
10. Chew EY, Clemons TE, Bressler SB et al (2014) Randomized trial of a home monitoring system for early detection of choroidal neovascularization home monitoring of the eye (HOME) study. *Ophthalmology* 121:535–544
11. Ferris FL 3rd. (1994) Results of 20 years of research on the treatment of diabetic retinopathy. *Prev Med* 23(5):740–742
12. Zapata MA, Arcos G, Fonollosa A, Abalades M, Oleñik A, Gutierrez E, Garcia-Arumi J (2017) Telemedicine for a general screening of retinal disease using nonmydriatic fundus cameras in optometry centers: three-year results. *Telemed J E Health* 23(1): 30–36
13. Guthrie R (2003) The use of medical examinations for employment purposes. *J Law Med* 11(1):93–102 Review
14. Thuraisingham C, Nalliah S (2013) The pre-employment medical-ethical dilemmas for GPs. *Aust Fam Physician* 42(4):249–251
15. Hutchinson A, McIntosh A, Peters J, O'Keeffe C, Khunti K, Baker R, Booth A (2000) Effectiveness of screening and monitoring tests for diabetic retinopathy—a systematic review. *Diabet Med* 17(7): 495–506 Review
16. Chan CK, Gangwani RA, McGhee SM, Lian J, Wong DS (2015) Cost-effectiveness of screening for intermediate age-related macular degeneration during diabetic retinopathy screening. *Ophthalmology*. 122(11):2278–2285
17. Hark LA, Katz LJ, Myers JS, Waisbourd M, Johnson D, Pizzi LT, Leiby BE, Fudenberg SJ, Mantravadi AV, Henderer JD, Zhan T, Molineaux J, Doyle V, Divers M, Burns C, Murchison AP, Reber S, Resende A, Bui TDV, Lee J, Crews JE, Saaddine JB, Lee PP, Pasquale LR, Haller JA (2017) Philadelphia telemedicine glaucoma detection and follow-up study: methods and screening results. *Am J Ophthalmol* 181:114–124
18. Pérez MA, Bruce BB, Newman NJ, Biousse V (2012) The use of retinal photography in nonophthalmic settings and its potential for neurology. *Neurologist*. 18(6):350–355
19. Chien JL, Sioufi K, Surakiatchanukul T, Shields JA, Shields CL (2017) Choroidal nevus: a review of prevalence, features, genetics, risks, and outcomes. *Curr Opin Ophthalmol* 28(3):228–237
20. Qiu M, Shields CL (2015) Choroidal nevus in the United States adult population: racial disparities and associated factors in the National Health and Nutrition Examination Survey. *Ophthalmology*. 122(10):2071–2083
21. Singh AD, Kalyani P, Topham A (2005) Estimating the risk of malignant transformation of a choroidal nevus. *Ophthalmology* 112:1784–1789
22. Kivela T, Eskelin S (2006) Transformation of nevus to melanoma. *Ophthalmology* 113:887–888
23. Tham YC, Li X, Wong TY, Quigley HA, Aung T, Cheng CY (2014) Global prevalence of glaucoma and projections of glaucoma burden through 2040: a systematic review and meta-analysis. *Ophthalmology*. 121(11):2081–2090
24. Ong HS, Levin S, Vafidis G (2013) Glaucoma detection using optic disc images from the English national screening programme for diabetic retinopathy. *J Glaucoma* 22(6):496–500
25. Treacy MP, O'Neill EC, Murphy M, O'Toole L, Delaney Y, O'Brien C, Connell PP (2016) Opportunistic detection of glaucomatous optic discs within a diabetic retinopathy screening service. *Eur J Ophthalmol* 26(4):315–320
26. Abrams LS, Scott IU, Spaeth GL, Quigley HA, Varma R (1994) Agreement among optometrists, ophthalmologists, and residents in evaluating the optic disc for glaucoma. *Ophthalmology*. 101(10): 1662–1667
27. Addis V, Oyeniran E, Daniel E, Salowe R, Zorger R, Lee R, Pistilli M, Maguire M, Cui Q, Miller-Ellis E, O'Brien JM, Sankar PS (2019) Non-physician grader reliability in measuring morphological features of the optic nerve head in stereo digital images. *Eye (Lond)* 33(5):838–844
28. Hadwin SE, Redmond T, Garway-Heath DF, Lemij HG, Reus NJ, Ward G, Anderson RS (2013) Assessment of optic disc photographs for glaucoma by UK optometrists: the Moorfields Optic Disc Assessment Study (MODAS). *Ophthalmic Physiol Opt* 33(5):618–624
29. Gangwani RA, McGhee SM, Lai JS, Chan CK, Wong D (2016) Detection of glaucoma and its association with diabetic retinopathy in a diabetic retinopathy screening program. *J Glaucoma* 25(1): 101–105
30. Silva R (2012) Myopic maculopathy: a review. *Ophthalmologica*. 228(4):197–213
31. ONCE (Organización Nacional de Ciegos Españoles) Afiliates to the ONCE (Organización Nacional de Ciegos Españoles) registration in 2018(2018). <https://www.once.es/dejanos-ayudarte/afiliacion/datos-de-afiliados-a-la-once>. Accessed 10 Jun 2020
32. Piyasena MMPN, Yip JLY, MacLeod D, Kim M, Gudlavalleti VSM (2019) Diagnostic test accuracy of diabetic retinopathy screening by physician graders using a hand-held non-mydriatic retinal camera at a tertiary level medical clinic. *BMC Ophthalmol* 19(1):89
33. Gosheva M, Klameth C, Norrenberg L, Clin L, Dietter J, Haq W, Ivanov IV, Ziemssen F, Leitritz MA (2017) Quality and learning curve of handheld versus stand-alone non-mydriatic cameras. *Clin Ophthalmol* 11:1601–1606
34. Alm M, Hautala N, Bloigu R, Huhtakangas J (2019) Comparison of optic disc evaluation methods in neurology emergency patients. *Acta Neurol Scand* 140(6):449–451
35. Bedard C, Sherry Liu S, Patterson C, Gerstein H, Griffith L (2017) Systematic review: can non-mydriatic cameras accurately detect diabetic retinopathy? *Diabetes Res Clin Pract* 129:154–159
36. Wong WL, Su X, Li X, Cheung CM, Klein R, Cheng C, Wong TY (2014) Global prevalence of age-related macular degeneration and disease burden projection for 2020 and 2040: a systematic review and meta-analysis. *Lancet Glob Health* 2(2):e106–e116
37. Au A, Gupta O (2011) The economics of telemedicine for vitreoretinal diseases. *Curr Opin Ophthalmol* 22(3):194–198

Publisher's note Springer Nature remains neutral with regard to jurisdictional claims in published maps and institutional affiliations.